

## A Case of Lobulated Spleen in a Holstein Cow

Ayşe HALIGUR \*  Ozlem OZMEN \*\* Mehmet HALIGUR \*\*

\* Department of Anatomy, Faculty of Veterinary Medicine, University of Mehmet Akif Ersoy, 15100, Burdur - TURKEY

\*\* Department of Pathology, Faculty of Veterinary Medicine, University of Mehmet Akif Ersoy, 15100, Burdur - TURKEY

**Makale Kodu (Article Code): KVFD-2009-275**

### Summary

A case of abnormal lobulation of spleen in a three years old Holstein cow was described after slaughter. Post mortem evaluation of the cow revealed three lobes and two projections at the spleen. The color of the spleen was normal but lymphoid hyperplasia was observed at the cut surface. Hilus of the spleen was located on 1/3 of the facies visceralis. Histopathological examination of the spleen revealed that lymphoid hyperplasia. No abnormality was observed other visceral organs. This is a first case of lobulated spleen in a three years old Holstein cow.

**Keywords:** *Lobulated spleen, Anomaly, Cow*

## Bir Holstein İnekte Loblu Dalak Olgusu

### Özet

Holstein ırkı, üç yaşlı bir inekte kesim sonrası dalakta anormal loblama saptandı. Postmortem incelemede dalağın üç lob ve iki çıkıntısı bulunduğu dikkati çekti. Dalağın rengi normaldi ancak kesit yüzünde lenfoid hiperplazi saptandı. Dalağın hilus'u, facies visceralis'in 1/3'lük kısmına yerleşmişti. Histopatolojik incelemede lenfoid hiperplazi dikkati çekti. Diğer iç organlarda anomali saptanmadı Bu 3 yaşlı bir Holstein ineğinde karşılaşılan ilk loblu dalak olgusudur.

**Anahtar sözcükler:** *Loblu dalak, Anomali, İnek*

### INTRODUCTION

The spleen is located in the left hypogastric region. It lays the cranial surface of the reticulum on the left side of the abdomen and vertically on the cranial end of the dorsal sac of the rumen <sup>1</sup>. This organ is soft, bright red to dark purple in color and highly vascular. It contains lymphoid tissue. Spleen's size and weight vary throughout life and under different conditions. Generally, shape of spleen has an elongated, oval outline. In adult cattle, its average weight is about 665-1155 g <sup>2-4</sup> width is about 10-15 cm and length is nearby 50 cm or and in the middle thickness of organs is about 2 to 3 cm <sup>2,4</sup>. Parietal surface is convex and related to diaphragm. The visceral surface is concave and related chiefly to the left face of rumen. The dorsal part is attached to narrow adjacent and the ventral part is free. The hilus is situated on the dorsal third of the visceral

surface, near the cranial border <sup>2,3</sup>.

Pathology of the spleen can be categorized as congenital abnormalities, splenomegaly, focal abnormalities (cystic masses, solid masses), vascular abnormalities, trauma and rupture or splenic clefts, notches and lobulations, accessory spleen, wandering spleen and polysplenia <sup>5,6</sup>. Congenital anomalies of spleen usually together with cardiac and visceral anomalies and rarely polysplenia syndrome may be seen <sup>7</sup>. In one study in two spleens reported in a Holstein calf <sup>8</sup>, other study in man indicated that polysplenia or asplenia may be seen.

The aim of this study was to report an unusual lobulation in a three years old Holstein cow. This is the first case of lobulated spleen in cattle.



**İletişim (Correspondence)**



+90 248 2344500/1544



ahaligur@hotmail.com

## CASE HISTORY

Material was occurred that it was butchered in which slaughterhouse of Burdur Power Confederation and it was not seen symptom of any illness. Spleen was fixed in 10% buffered formalin. It was examined and measured macroscopically for anatomo-pathological findings. Tissue sample of the spleen processed for histopathological examination. After routine pathology procedure it was blocked in paraffin, sections were cut 5  $\mu$  thickness and stained with Haematoxylin and Eosin (HE).

The cow was healthy, 3 years old, 752 kg body weight Holstein cow and no clinical symptoms observed related spleen abnormality. During the slaughter only one anomalous organ was spleen, the other organs were normal appearance and situs. Post mortem evaluation of the cow revealed that spleen was highly vascular and dark violet in color and weighted 412 g. Spleen length which between points was 26 cm and in the middle its thickness was width 5.1 cm. Splenic hilus was located in cranial part of organs and distribution of the vessels were normal one enter. It was very different form, both extremitas cranialis and caudalis had thin beginning, and had different two process and three lobes respectively in the spleen (Fig. 1). The one splenic process was located in extremitas cranialis. It length was 0.844 cm and width 1.734 cm. The other process was located on margo cranialis. It length was 2.261 cm and width 4.345 cm. The first lobe was located on the dorsal part of the margo caudalis. It arcuated caudally and length (margo caudalis to point of the process) was 8.5 cm and in the its middle width was 2 cm. The second lobe was located on distal part of margo caudalis and its had finger like curled shape. It direction was caudal, ventral and cranial respectively. Length of first curl was measured 5.1 cm, second curl was 4.2 cm and width of this process was measured 3.4 cm. The third lobe was look like continuing to organ and located to extremitas caudalis.

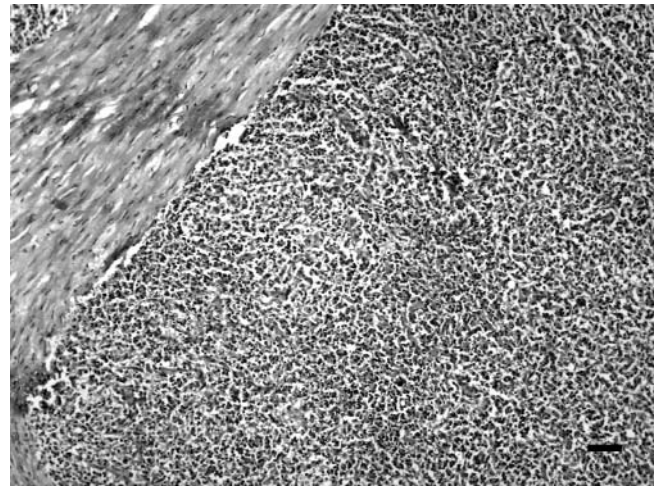


**Fig 1.** Macroscopic view of spleen

**Şekil 1.** Dalağın makroskopik görünüşü

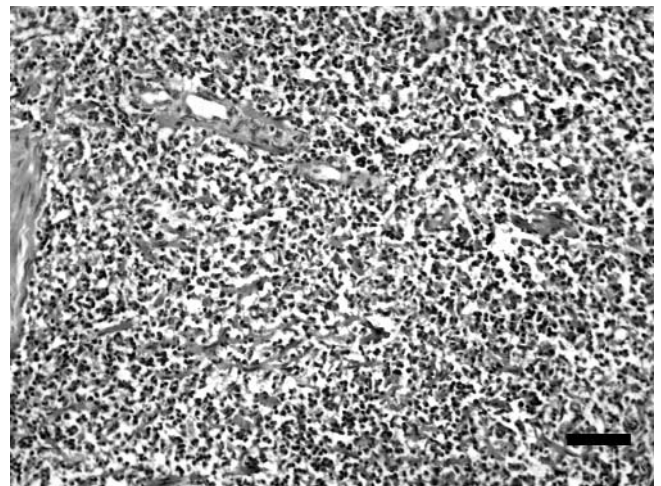
End of the process was curving trough to cranial. Length of the first part of third lobe was 8.5, and last part was 3.9 cm. Width of third process was measured as 3.2 cm. Hilus of the spleen was located on 1/3 of the facies visceralis.

Gross examination of the spleen revealed that marked lymphoid hyperplasia at the cut surface. The organ was not flat, and thickness of the spleen was more than normal. The body of the organ was smaller and harder than normal. No abnormality was observed in other organs. Histology of the spleen revealed that slight lymphoid hyperplasia (Fig. 2, 3).



**Fig 2.** Microscopic observation of spleen, HE, Bar = 200  $\mu$ m

**Şekil 2.** Dalağın mikroskopik görünüşü, HE, Bar = 200  $\mu$ m.



**Fig 3.** High power microscopic appearance of the spleen, HE, Bar = 100  $\mu$ m.

**Şekil 3.** Dalağın büyük büyütmedeki görünüşü, HE, Bar = 100  $\mu$ m

## DISCUSSION

The spleen lies vertically on the cranial end of the dorsal sac of the rumen and the cranial surface of the

reticulum on the left side of the abdomen <sup>1</sup>. In this case localization of the spleen was normal. Lobulated spleen is uncommon splanic abnormality. Generally spleen abnormalities are together with the other organ abnormalities or pathologic processes, even very complex and multiple abnormalities like as schistosomus reflexus spleen is generally normal <sup>9,10</sup>. But in this study, the other organs were normal shape and situs, only spleen lobulated. Generally, organ is soft, bright red to dark <sup>2,3</sup> while in this study was highly vascular and dark violet in color. According to literature <sup>2</sup>, length of spleen is nearby 50 cm and width is about 15 cm and middle thickness of the organ is about 2 to 3 cm. In present case, we observed to length of between extremitas was 26 cm, and width of spleen was 5.1 cm. While the average weight is generally about 665-1155 g <sup>2-4</sup> we observed the organ's weight as 412 g. Localization of the hilus was similar to the previous knowledge <sup>2,3</sup>.

During development, the spleen originates from splanic mesoderm (mesenchyme that surrounds the gut endoderm), which arises from splitting of the lateral plate mesoderm into somatic mesoderm (body wall) and splanic mesoderm <sup>11</sup>. In vertebrates, the mesodermally derived spleen normally displays left-handed asymmetry <sup>12</sup> and has been considered to be a landmark organ for detecting laterality defects <sup>13</sup>. In human, the fetal spleen is lobulated, but these lobules normally disappear before birth. Splenic lobulations may persist along the medial part of the spleen <sup>5,14,15</sup>, but there is no information about animal splanic lobulation in embryonic development. The pathogenesis of this spleen anomaly is a result of abnormality of embryonic curvature <sup>16</sup>. In the present case, the cause could not be established because of the any clinical history.

In this study, histopathological finding was revealed to only lymphoid hyperplasia. Other organs prepared were very normal. Lymphocytes were prominent within the splenic parenchyma. Various abnormalities have been determined in literature. These are generally congenital and the organs of it very changed (ventricular defect, atrial defect, atonia, hydrocephalus etc) <sup>9</sup>. But this is the first report of spleen anomaly seen in normal cow.

As a conclusion, this paper reported that unusual splenic lobulation in normally slaughtered, 3 years old Holstein cow. Post mortem evaluation of the cow organs revealed three lobes and two projections at the spleen. No abnormality was observed other visceral organs.

## REFERENCES

- Nickel R, Schummer A, Seiferle E:** Milz, Lien, Splen. In, Lehrbuch der Anatomie der Haustiere. Vol. 2. 6th ed. Eingeweide, 213-218. Paul Parey, Berlin, Hamburg, 1987.
- Sisson S:** Lymphatic system, Spleen. In, Getty R (Ed): The Anatomy of the Domestic Animals. 5th ed. 1063, WB Saunders Company, London, 1975.
- Dursun N:** Veteriner Anatomi II, 7. baskı. Medisan Yayınevi, 303-307, 2000.
- Bahadır A, Yıldız H:** Veteriner Anatomi. Hareket Sistemi ve İç Organlar. 2. baskı. s. 245-247, Ezgi Kitabevi, Bursa, 2008.
- Gayer G, Zissin R, Apter S, Atar E, Portnoy O, Itzchak Y:** CT findings in congenital anomalies of the spleen. *Br J Radiol*, 74, 767-772, 2001.
- Haziroğlu R:** Hemapoietik sistem. In, Haziroğlu R, Milli Ü (Eds): Veteriner Patoloji II. 2. baskı. s. 337, Medipress, Malatya, 2001.
- Ahmetoğlu A, Koflucu P, Sarı A, Gümele HR:** Polispleni sendromunda radyolojik bulgular. *Tanısıl ve Girişimsel Radyoloji*, 8, 510-512, 2002.
- Fisher KRS, Wilson MS, Partlow GD:** Abdominal situs inversus in a Holstein calf. *Anat Rec*, 267, 47-51, 2002.
- Newman SJ, Bailey TL, Jones JC, DiGrassie WA, Whittier WD:** Multiple congenital anomalies in a calf. *J Vet Diag Invest*, 11, 368-371, 1999.
- Laughton KW, Fisher KRS, Halina WG, Partlow GD:** Schistosomus reflexus syndrome: A heritable defect in ruminants. *Anat Histol Embryol*, 34, 312-318, 2005.
- Funayama N, Sato Y, Matsumoto K, Ogura T, Takahashi Y:** Coelom formation: Binary decision of the lateral plate mesoderm is controlled by the ectoderm. *Development*, 126, 4129-4138, 1999.
- Boorman CJ, Shimeld SM:** The evolution of left-right asymmetry in chordates. *BioEssays*, 24, 1004-1011, 2002.
- Aylsworth AS:** Clinical aspects of defects in the determination of laterality. *Am J Med Genet*, 101, 345-355, 2001.
- Shirkhoda A:** Diagnostic pitfalls in abdominal CT. *Radiographics*, 11, 969-1002, 1991.
- Moore KL, Persaud TVN:** The Digestive System. In, Moore KL, Persaud TVN (Eds): The Developing Human Clinically Oriented Embryology. 6th ed., pp. 271-302, WB Saunders, Philadelphia, 1998.
- Arey LB:** Developmental Anatomy. A Textbook and Laboratory Manual of Embryology. 7th ed., pp. 342-374, WB Saunders, Philadelphia, 1954.